

cases requiring a return to the operating room for control of bleeding. Remarkably, none of these were currently undergoing aspirin therapy.

Infection developed in two patients (2.6 percent). Both cases were managed effectively with antibiotics. Hypertrophic scarring was noted in five patients (6.4 percent), all of whom responded to three or fewer corticosteroid infiltrations (triamcinolone 25 mg/ml). No contour deformities, including collapse or flattening of the helical rim, were observed.

The helical advancement flap shows great versatility when considering defects from 1.5 to 3 cm. Our review of an unprecedented 78 cases affirms that the procedure carries an extremely low risk of complications, with no total flap failures. The rate of hematoma formation (5.1 percent) deserves mention. Fibrin sealants or possibly the use of drains or bolsters should be considered. However, hematomas rarely cause flap failure if properly evacuated. Hypertrophic scarring and keloids may be managed with intralesional corticosteroid injections with application of pressure, massage, and radiotherapy for refractory cases. Measures can also be taken to further improve cosmesis, with examples being the Burow triangle to decrease flap tension and use of Z-plasty to minimize undesired notching of the auricle. In addition, edge eversion may be improved with a vertical or buried mattress suture diminishing the risk of notching.²

DOI: 10.1097/PRS.0b013e3181d51546

Neil Tanna, M.D., M.B.A.

Division of Otolaryngology–Head and Neck Surgery
The George Washington University
Washington, D.C.

Matthew S. Clary, M.D.

Department of Otolaryngology–Head and Neck Surgery
Thomas Jefferson University
Philadelphia, Pa.

David E. Conrad, M.D.

Department of Otolaryngology
Albert Einstein College of Medicine
Bronx, N.Y.

Arjun S. Joshi, M.D.

Division of Otolaryngology–Head and Neck Surgery
The George Washington University
Washington, D.C.

William H. Lindsey, M.D.

Plastic Surgery Associates of Northern Virginia, Ltd.
McLean, Va.

Correspondence to Dr. Tanna
Division of Otolaryngology–Head and Neck Surgery
The George Washington University
2150 Pennsylvania Avenue, NW
Washington, D.C. 20037
ntanna@gwu.edu

Poster presented at Plastic Surgery 2007, the 76th Annual Meeting of the American Society of Plastic Surgeons, in Baltimore, Maryland, October 26 through 31, 2007.

DISCLOSURE

The authors have no conflicts of interest to report.

REFERENCES

1. Elshahy NI. Reconstruction of the ear after skin and perichondrium loss. *Clin Plast Surg.* 2002;29:187–200.
2. Ramsey ML, Marks VJ, Klingensmith MR. The chondrocutaneous helical rim advancement flap of Antia and Buch. *Dermatol Surg.* 1995;21:970–974.
3. Brodland DG. Auricular reconstruction. *Dermatol Clin.* 2005; 23:23–41.
4. Furnas DW. Complications of surgery of the external ear. *Clin Plast Surg.* 1990;17:305–318.

Staggered Wedge Technique for Ear Reconstruction

Sir:

Simple wedge resection is widely used for reconstruction of full-thickness helical rim defects smaller than 1.0 to 1.5 cm.¹ For reconstruction of defects up to 2.5 cm, crescentic or star excisions can be used. However, these techniques can frequently cause skin contraction and ear cupping.

For defects smaller than 2.5 to 2.8 cm, we use a modification of the classic wedge resection, in which a full-thickness Burow triangle is excised superiorly or inferiorly to the helical rim defect. The principle of staggering the wedge, similar to the one of staggering an ellipse,² allows a better distribution of elastic forces than other techniques.

The lesion is outlined and the excision margins are decided. The planned defect is converted into a full-thickness rectangle. The width of defect is marked as AB. A Burow triangle of antihelix and concha is planned cranially or caudally to the helical defect. The triangle base is marked as A1B1 and has to be the same length as AB (defect). The triangle has to be isosceles and the bisector of the vertex angle has to be oriented toward a point localized at the root of the helix; this point is at the center of an ideal hemicircumference drawn at the level of the ear upper pole. The triangle is excised full thickness. The helical and antihelical edges are advanced and sutured together. The continuity of the helix and antihelix is reestablished in three layers, resulting in a Z suture line (Fig. 1).

We treated 52 consecutive patients from 2001 to 2004. Surgical margins were 0.5 cm for squamous cell carcinoma, 0.3 cm for basal cell carcinoma, and 0.2 cm for chondrodermatitis nodularis. The defect size after tumor resection with surgical margin control ranged from 12 to 28 mm. Patients had a follow-up period of 6 to 24 months.

All the defects were closed primarily without tension along the suture line. There were no early or late

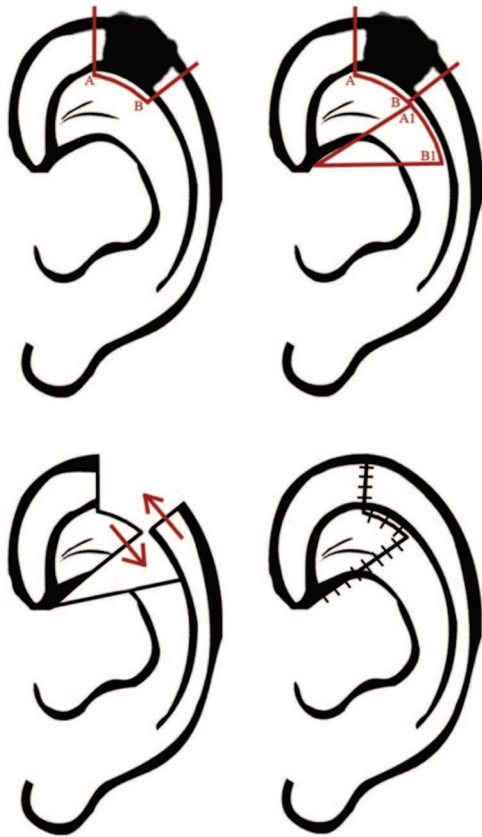


Fig. 1. Staggered wedge technique.

complications. Aesthetic results were satisfactory in 49 patients (94 percent), with an acceptable decrease of auricular size.

Our technique is quite similar to the one described by Ferri, in terms of excising a full-thickness Burrow triangle but lacks the second incision at the helical root level.³ Aesthetic results of the reconstructed ear are guaranteed by balancing forces on the frontal and sagittal planes. Furthermore, anatomical landmarks and relative proportions are preserved.

The range of defects that can be reconstructed by the staggered wedge technique is usually between 1.0 and 2.5 cm. Larger ears can tolerate larger wedge excisions, up to 2.8 cm in our experience (Fig. 2). Helical defects larger than 2.8 to 3 cm definitively require flap reconstruction such as with the Antia and Buch flap⁴ or other modifications.⁵

DOI: 10.1097/PRS.0b013e3181d515c9

Fabrizio Schonauer, M.D., Ph.D.

Domenico Campa, M.D.

Antonio Monaco, M.D.

Guido Molea, M.D., Ph.D.

University "Federico II"
Naples, Italy

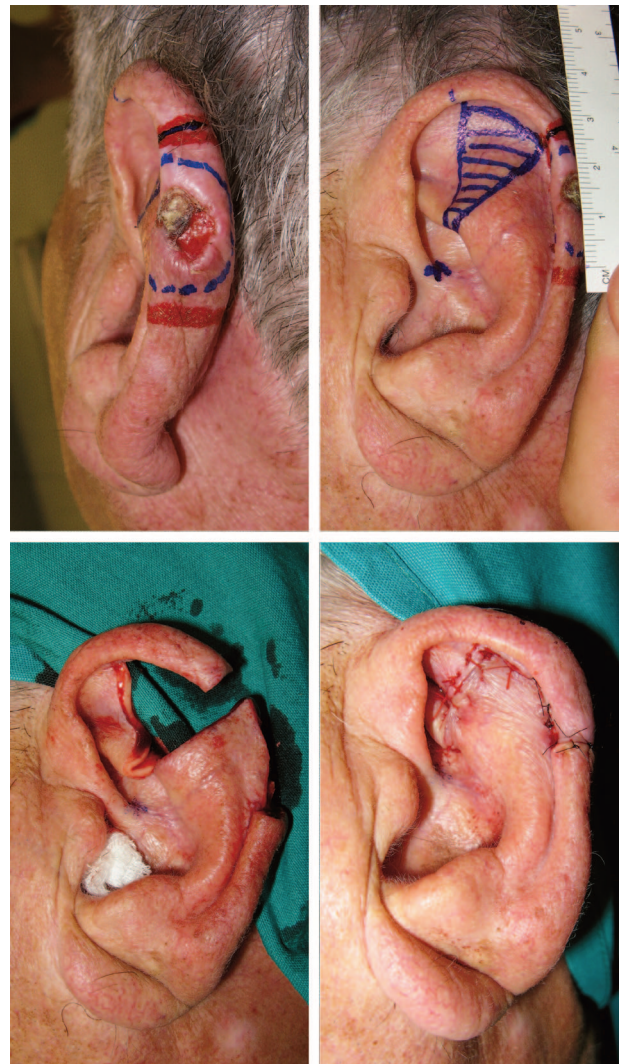


Fig. 2. Defect of 2.8 cm of helix reconstructed with the staggered wedge technique.

Correspondence to Dr. Schonauer
Department of Plastic Surgery
University "Federico II"
Via Pansini 5
Naples 80122, Italy
fschona@libero.it

REFERENCES

1. Elsayh NI. Reconstruction of the ear after skin and cartilage loss. *Clin Plast Surg.* 2002;29:201–212.
2. Evans DM. The staggered ellipse. *Br J Plast Surg.* 2000;53:240–242.
3. Ferri M. Treatment of partial losses of the helix. *Plast Reconstr Surg.* 1998;101:2011–2012.
4. Antia NH, Buch VI. Chondrocutaneous advancement flap for the marginal defect of the ear. *Plast Reconstr Surg.* 1967;39:472–477.
5. Fata JJ. Composite chondrocutaneous advancement flap: A technique for the reconstruction of marginal defects of the ear. *Plast Reconstr Surg.* 1997;99:1172–1175.