



CASE REPORTS

Redefinition of the helical rim in cauliflower-ear surgery

F. Schonauer, I. La Rusca, J. A. Pereira* and G. Molea

University of Naples 'Federico II', Naples, Italy; and *Department of Plastic Surgery, St Thomas' Hospital, London, UK

SUMMARY. Cauliflower ear is a serious deformity of the auricle induced by single or repeated injury to the external ear. Few papers deal with surgical techniques for correcting this deformity. We describe the use of ipsilateral excess cartilage to restore the helical rim. © 2002 The British Association of Plastic Surgeons

Keywords: cauliflower ear, cartilage graft.

Case report

A 29-year-old man presented with a cauliflower deformity of the right external ear. This was related to squeezing of a skin 'spot' on the posterior aspect of his ear 3 months earlier. After this, a swelling developed, which became persistent.

Examination revealed a thickening of the upper ear with disruption of the antihelical crura contour and loss of helical-rim definition; an extra third crus, horizontally orientated, was present,

which was not related to a pre-existing Stahl's ear (Fig. 1). X-ray examination showed no calcification within the cartilage.

Surgery was performed under local anaesthesia. A posterior approach, halfway between the sulcus and the helical rim, was used to deglove the cartilagenous skeleton. No skin ellipse was excised. Having exposed the cartilage, it was apparent that there were anterior and posterior lamellae. A plane was developed between these two structures (Fig. 2), and the posterior layer

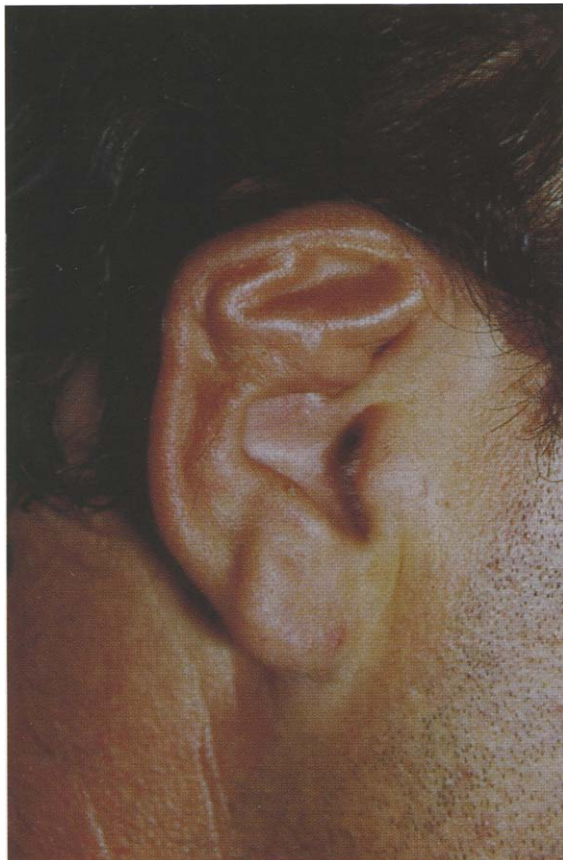

Figure 1—Cauliflower deformity of the right external ear.

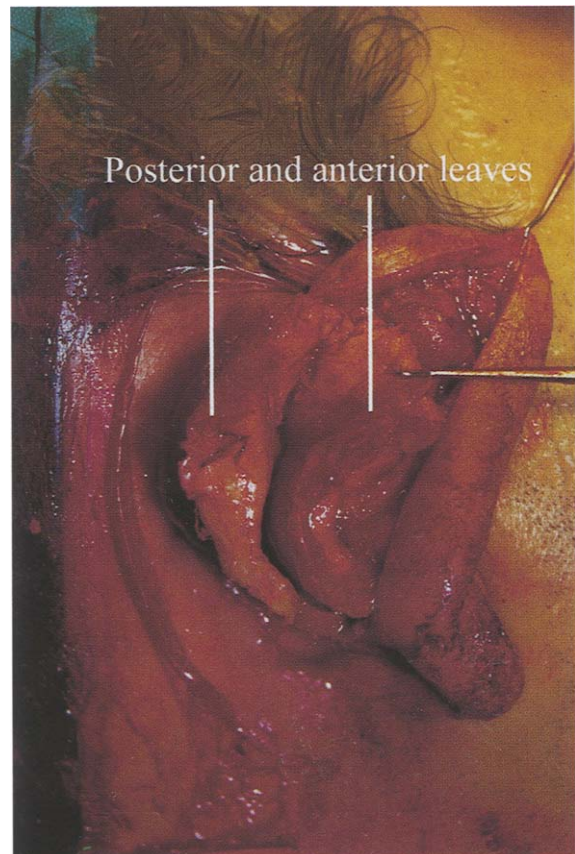


Figure 2—Intraoperative view showing the presence of two well-defined leaves.

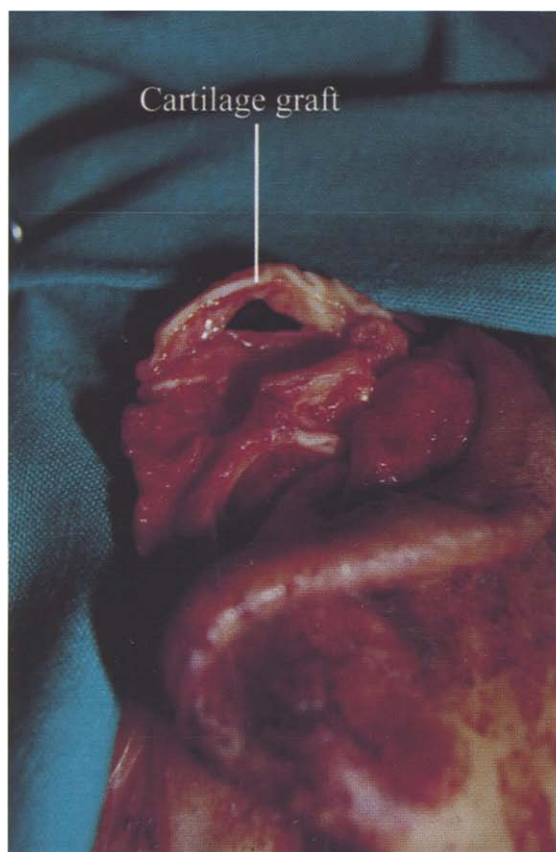


Figure 3—Intraoperative view showing the cartilage graft in place.

was excised at its base. The anterior lamella was tangentially thinned, and the antihelix was re-sculpted. A strip of cartilage, measuring 5.5 cm × 0.6 cm, obtained from the excess cartilage fragment, was carved to reconstruct the upper pole of the helical rim. This graft was sutured into position using four 6/0 Monocryl sutures, two for each extremity (Fig. 3). The skin was re-draped, and sutured with 5/0 Vicryl. No drain was left in situ. Paraffin-gauze bolster sutures were used to splint the reshaped helical groove. A head bandage was applied for 7 days. No postoperative haematoma occurred. The bolster sutures were removed 10 days postoperatively, and subsequently a tennis band was worn for 6 weeks. Postoperative swelling was observed in the lower antihelical fold. The cosmetic result at 10 months was satisfactory to the patient (Fig. 4).

Histological examination of the excess cartilage fragment showed cartilaginous tissue surrounded by fibrous tissue with haemosiderin deposits.

Discussion

A cauliflower-ear deformity occurs when a haematoma strips perichondrium from the cartilage, resulting in the formation of a new bilaminar structure. Our patient developed a haematoma after relatively minor trauma from squeezing a 'spot'. Simple aspiration immediately after the trauma was not performed, allowing organisation of the haematoma into fibrocartilage. Studies show that after as little as 3 weeks a sub-perichondrial haematoma can result in new cartilage formation.¹ Once cartilage neoformation is established, surgical correction

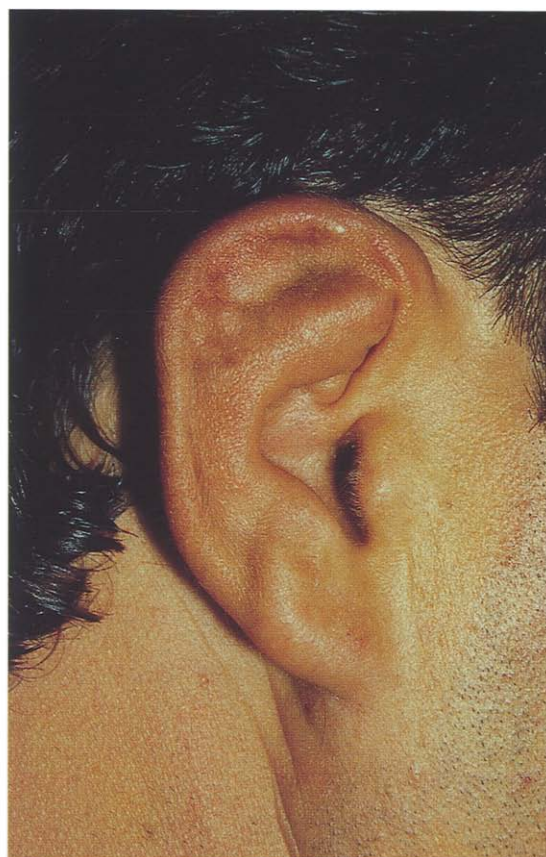

Figure 4—Final result at 10 months.

is the treatment of choice if cosmetic improvement is sought. Early surgery gives better results. The longer the problem is left uncorrected, the more difficult the reconstruction becomes.

In our case, we focused on correcting three elements: first, the presence of a double cartilage layer; second, the loss of definition of the antihelix; and finally, the lack of the helical rim.

Complete removal of the fibrocartilage has been advocated, followed by a classic otoplasty to correct the antihelix.^{2,3} We support excision of the fibrocartilage layer, but find tangential shaving effective in re-sculpting the folds as required. The posterior layer of cartilage provides a 'free' donor site for a graft to reconstruct the helical rim. The graft in this case was carved as in the Musgrave technique for marked lop-ears deformity,⁴ and secured with sutures at its extremities only.⁵

In conclusion, the use of the excised lamella of fibrocartilage as a source of graft material can be successful in correction of the cauliflower-ear deformity. Although histologically the cartilage is not fully organised, it appears to hold its shape and volume when used in this way.

References

1. Ohlsén L, Skoog T, Sohn SA. The pathogenesis of cauliflower ear: an experimental study in rabbits. *Scand J Plast Reconstr Surg* 1975; 9: 34–9.

2. Giffin CS. Wrestler's ear: pathophysiology and treatment. *Ann Plast Surg* 1992; 28: 131–9.
3. Vogelin E, Grobbelaar AO, Chana JS, Gault DT. Surgical correction of the cauliflower ear. *Br J Plast Surg* 1998; 51: 359–62.
4. Musgrave RH. A variation on the correction of the congenital lop ear. *Plast Reconstr Surg* 1966; 37: 394–8.
5. Brent B. The acquired auricular deformity: a systematic approach to its analysis and reconstruction. *Plast Reconstr Surg* 1977; 59: 475–85.

John A. Pereira FRCS, Specialist Registrar in Plastic Surgery

St Thomas' Hospital, Lambeth Palace Road, London SE1 7EH, UK.

Correspondence to Dr Fabrizio Schonauer, Corso Vittorio Emanuele 23, 80122 Napoli, Italy.

Paper received 17 August 2001.

Accepted 25 October 2001, after revision.

The Authors

Fabrizio Schonauer MD, Specialist in Plastic Surgery

Ivan La Rusca MD, Plastic Surgery Trainee

Guido Molea MD, Professor in Plastic Surgery

University of Naples 'Federico II', Naples, Italy.

British Journal of Plastic Surgery (2002)

© 2002 The British Association of Plastic Surgeons

doi:10.1054/bjps.2001.3729

The 6p deletion syndrome: a new orofacial clefting syndrome and its implications for antenatal screening

A. Topping, P. Harris and A. L. H. Moss

Department of Plastic and Reconstructive Surgery, St George's Hospital, London, UK

SUMMARY. Foetal genetic screening has become the centre of the ethical debate surrounding the screening of foetuses for chromosomal defects to help create 'eugenic' children with either perceived advantageous characteristics or traits that could be used to medically aid unhealthy siblings. This report highlights the problems facing the medical establishment by citing, by way of example, a case of a genetic abnormality producing a clefting syndrome. The 6p deletion syndrome was first described almost 20 years ago, and the evidence is mounting for its inclusion as an orofacial clefting syndrome. This case report includes a description of the syndrome, the method used for detecting chromosomal aberrations and a comparison with other reports of the syndrome published to date. However, by pursuing a genetic-testing policy at our unit to detect new abnormalities or to help substantiate previously reported abnormalities, the way could be left open for its subsequent abuse by parents and corporations alike, so having implications not only for the individual but also for the unit performing the test. A brief synopsis is therefore also provided regarding the current circumstances of foetal screening in the UK. © 2002 The British Association of Plastic Surgeons

Keywords: 6p deletion syndrome, screening, orofacial clefting, ethics.

Abnormalities of the short arm of chromosome 6 are now known to be associated with orofacial clefting. The literature contains 16 case reports where either a deletion or a translocation involving the short arm has been found on routine chromosomal analysis. Out of these 16 cases, 10 had an orofacial cleft as part of the presenting features. The so-called '6p syndrome' has now been suggested as a cause of orofacial clefting. The discovery of the 6p syndrome has only been possible in the past 10 years, subsequent to more accurate techniques enabling higher-powered analysis of the kilobases of chromosomes. Here, we report a patient who was found to have a deletion within the short arm of chromosome 6, and who manifested some of the phenotypic traits of the 6p syndrome reported to date, adding further weight to its inclusion as a clefting syndrome. A review of modern techniques of chromosomal analysis is presented, with a brief description of the sites on chromosome 6 where abnormalities associated with and without clefting

have been reported. Finally, the relative moral and ethical benefits of chromosomal testing are discussed with regard to antenatal screening.

Case report

The patient or proband is the second child of non-consanguineous parents. She has an elder healthy sibling with no abnormalities, and there is no family history of relevance. Mild hydronephrosis was diagnosed antenatally on routine scanning. The child was born to a 28-year-old mother by ventouse delivery at 38 weeks' gestation following an otherwise normal pregnancy. Birth weight was 3006 g, and examination revealed a right-sided complete cleft lip and a cleft of the primary palate (Figs 1 and 2). The child was admitted to the Special Care Baby Unit because of metabolic acidosis on cord pH testing. She was treated with albumin and required oxygen (26%) for 2 days. Trimethoprim 2 mg kg⁻¹ per day was given prophylactically for the hydronephrosis, which resolved spontaneously. Mild