

REVIEW

A Surgical Algorithm for Partial or Total Eyebrow Flap Reconstruction

GIUSEPPE ACCARDO, MD,^{1*} ACHILLE AVETA, MD,² ELENA AMBROSINO, MD,¹ BIANCA ACETO, MD,¹
 ANNALENA DI MARTINO, MD,¹ AND FABRIZIO SCHONAUER, MD, PhD, Prof¹

¹Unit of Plastic and Reconstructive Surgery, "Federico II" University Hospital, Naples, Italy

²Unit of Plastic and Reconstructive Surgery, "Campus Bio-Medico" University Hospital, Rome, Italy

The eyebrow is one of the five aesthetic sub-units of the forehead and it plays a key role in communication and facial expression. Reconstruction of this region can be challenging. Several methods have been described, mostly based on the size of the defect and on the part of the eyebrow that they involve. We describe our experience in 48 patients underlining the importance of a surgical algorithm for repairing eyebrow defects.
J. Surg. Oncol. © 2015 Wiley Periodicals, Inc.

KEY WORDS: oncological skin lesions; eyebrow; immediate reconstruction; flap reconstruction; algorithm; V-Y flap; H flap; superficial temporal artery island flap

INTRODUCTION

The forehead aesthetic unit consists of 5 sub-units: central forehead, lateral forehead and the left and right eyebrow [1].

Despite the bi-dimensional nature of the procedure, eyebrow reconstruction is not always a simple matter. Both the position and the continuity of the eyebrow hairline play an important role in the overall harmony of the face. As a consequence, in cases of oncological or trauma defects the main target of reconstructive surgery is to re-establish eyebrow continuity in the search for symmetry.

Skin defects in hair-bearing regions present a reconstructive challenge for plastic surgeons as replacement tissue must have the same characteristics as the recipient area including similar color, thickness and hair-bearing capacity. The hairs of the eyebrow have peculiar and unique characteristics: they are short in length, small in diameter and are slow growing. Therefore finding replacement tissue with all 3 characteristics is very challenging.

Most common causes of eyebrow loss are due to burn, trauma and surgical excision. Herein we report on a series of eyebrow defects following elective skin excisions. Our study involves a homogeneous group of skin defects allowing for immediate reconstruction following resection surgery thanks to the healthy perilesional skin available for flap surgery. Upon review of our clinical series, an algorithm was formulated for eyebrow reconstruction which assigns different pedicled flaps to five possible defect sizes and is presented herein.

PATIENTS AND METHODS

Forty-eight patients (18 male and 30 female) with eyebrow defects, aged 28 to 77 years, were operated on between 2004 and 2014. The series included 29 defects located on the left and 19 on the right eyebrow. Defects were secondary to elective removal of skin lesions which were excised in accordance with oncological principles.

Surgical procedures were performed under local or general anaesthesia according to the invasiveness of the procedure.

To measure the aesthetic outcome of reconstructed eyebrows, patients' satisfaction on overall outcome of their reconstructed eyebrows was assessed using a Visual Analogue Scale (VAS) [2] with a range between 1 and 10, whereby 1 denoted "dissatisfaction" and

10 denoted "very satisfied." Moreover, a blind panel of three impartial observers (one medical student, one plastic surgery resident and one plastic surgery specialist) evaluated the aesthetic outcome of reconstructed eyebrows. The observers were asked to look at the post-operative digital photos of all patients and express their personal opinion on the overall cosmetic appearance of the reconstructed eyebrow using the Visual Analogue Scale for aesthetic outcome with a range from 1 to 10, whereby 1 meant "poor appearance" and 10 meant "excellent appearance."

Applied Anatomy

The vascular network of the eyebrow is formed by branches of the supratrochlear artery the supraorbital artery, the superficial temporal artery and their associated veins. Amongst these, the supraorbital artery is located in the middle and anastomoses with the frontal branch of the superficial temporal, the ipsilateral and the contralateral supratrochlear arteries [3].

Surgical Techniques

Direct closure represented the simplest and most effective corrective remedy for small defects. The incision lines were extended beyond the limit of the eyebrow in order to create a vertically oriented ellipse ensuring that the upper and lower margins of the eyebrow were joined together. In cases of larger defects different flaps were used sourced from the rich vascularisation of the eyebrow area.

*Correspondence to: Giuseppe Accardo, MD, C.so Vittorio Emanuele, 21/B; Torre del Greco, 80059, NA., Unit of Plastic and Reconstructive Surgery, University of Medicine Federico II, Via S. Pansini 5, Naples, Italy. Fax: 0039 081 7463698. E-mail: gaccardo@hotmail.it

Received 14 June 2015; Accepted 13 September 2015

DOI 10.1002/jso.24054

Published online in Wiley Online Library
 (wileyonlinelibrary.com).

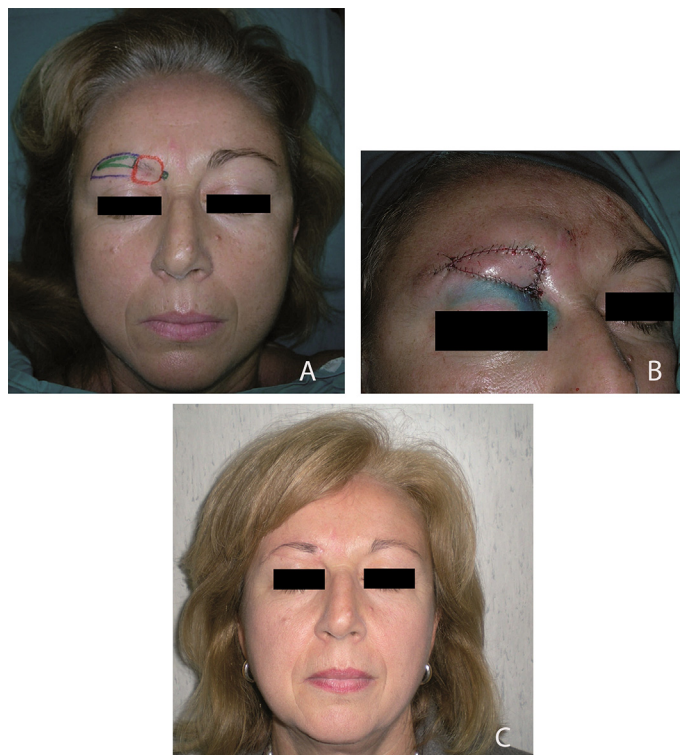

Fig. 1. **A:** 1 cm wide local excision of right eyebrow melanoma and VY flap planning. **B:** Flap advanced on a random subcutaneous pedicle. **C:** Two years follow up.

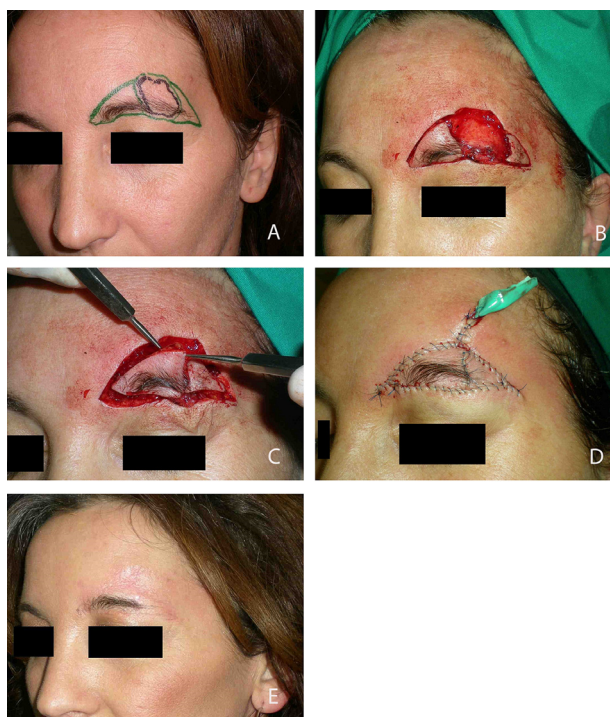

Fig. 2. **A:** Basal cell carcinoma of the left eyebrow and double VY flap planning. **B:** Skin defect after surgical excision. **C:** Double VY flap advanced on a random subcutaneous pedicle. **D:** Double VY flap closure. **E:** Double VY flap reconstruction at 8 months follow up.

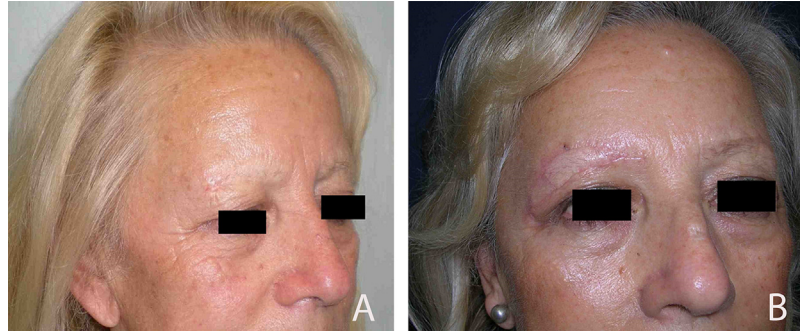

Fig. 3. **A:** Basal cell carcinoma of the right eyebrow in a 65 years old patient. **B:** Double VY flap eyebrow reconstruction at 8 months follow-up.

It was found that a single rectangular advancement flap was a good option for reconstruction of small eyebrow defects. A variant of this method, the H flap, was used which involved harvesting two rectangular advancement flaps lateral to the defect when defects were located in the central part of the eyebrow. Removing two Burow's triangles at the base of each flap was rarely deemed necessary.

The subcutaneous pedicle V-Y flap with random vascularization represented a reliable surgical technique for this aesthetic sub-unit (Fig. 1A–C). The flap was dissected out in a subcutaneous plane with careful attention given to preserving branches of the supratrochlear or supraorbital arteries, veins and nerves. Flap advancement relied on the elasticity of the tissues that are not particularly mobile in this area of the

forehead. A double V-Y flap was used for defects of up to one half of the eyebrow, doubling the mobility of the two flaps (Figs. 2A–E and 3A–B).

For larger defects affecting circa 50% or more of the eyebrow, a V-Y flap with axial vascularization and more aggressive skeletonization of the vascular pedicle was preferred [6]. In such cases, during pre-operative planning, the hand-held Doppler was necessary in order to identify and mark the course of the artery to be used for the flap.

In cases of more laterally located defects where flap advancement was in the medial-to-lateral direction, vascularization was dependent upon the supra-trochlear artery. In such cases, flap dissection was performed from medial to lateral in the subgaleal plane. The flap was raised by dividing the thin frontalis muscle attachments from the upper margin of the skin island. The supra-trochlear artery and vein were then intramuscularly dissected and skeletonised in the area where the fibres of the frontalis muscle blended with those of the corrugators supercilii, thus providing a perforator-like flap (Fig. 4A and B) [4].

Alternatively, in the case of more medially located defects where flap advancement was in the lateral-to-medial direction, vascularisation was dependent upon the frontal branch of the superficial temporal artery. A strip of fascia underneath the flap was dissected out and advanced along with the superficial temporal artery pedicle [5].

In both cases the pedicle was dissected under magnification with extreme care using surgical loops, with attention given to preserving the supraorbital or the facial nerve temporal branch.

If a defect exceeded half the length of the eyebrow or affected almost the entire aesthetic sub-unit, a local flap was not indicated. Amongst the surgical techniques applicable we favoured the superficial temporal artery island flap (Fig. 5A–E). A Doppler probe was used preoperatively to trace the peripheral branches from the lateral parietal area of the superficial temporal artery. The hairy skin island was marked according to defect size. Care was taken in planning the hair direction of the skin island. The superficial temporal artery and vein were not skeletonized, but instead were included within a broad strip of superficial temporalis fascia. The anterior branch of the superficial temporal artery had to be divided distal to its take-off from the main superficial temporal artery in order to allow the mobility of the flap pedicle. A generous subcutaneous tunnel was made countering the pre-auricular area to the brow recipient site. In this way there was no constriction of the pedicle within the tunnel. Once in position, the island flap was inset and dressed [6,7].

RESULTS

Histological examinations were carried out on the 48 lesions excised, which were classified as follows: 25 basal cell carcinomas (of which 2 were recurrent), 8 epidermal nevi, 5 Bowen's disease, 4 keratosis, 2 angioma, 2 Hutchinson's lentigo and 2 melanoma. Of the last 2 patients, one underwent a 1 cm local excision of a 1.3 mm

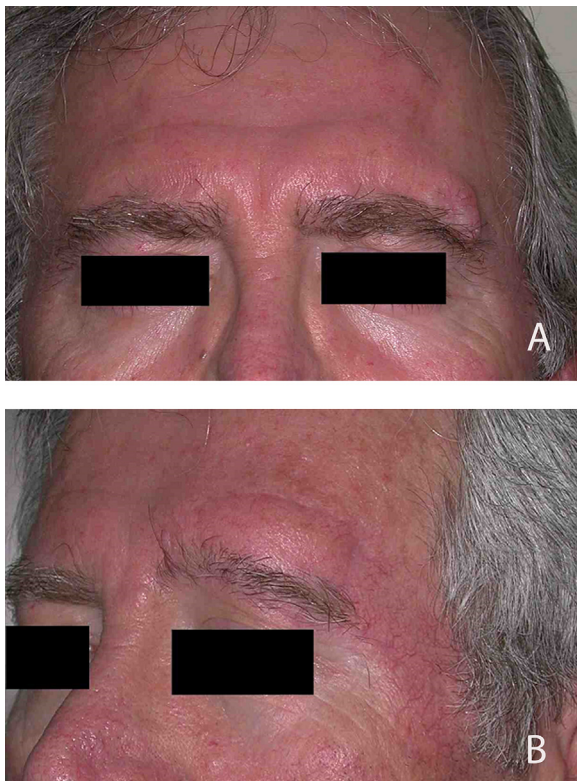

Fig. 4. **A:** Recurrent basal cell carcinoma of the left eyebrow in a 76 years old patient. **B:** Supratrochlear artery based V-Y flap reconstruction at 10 months follow-up.

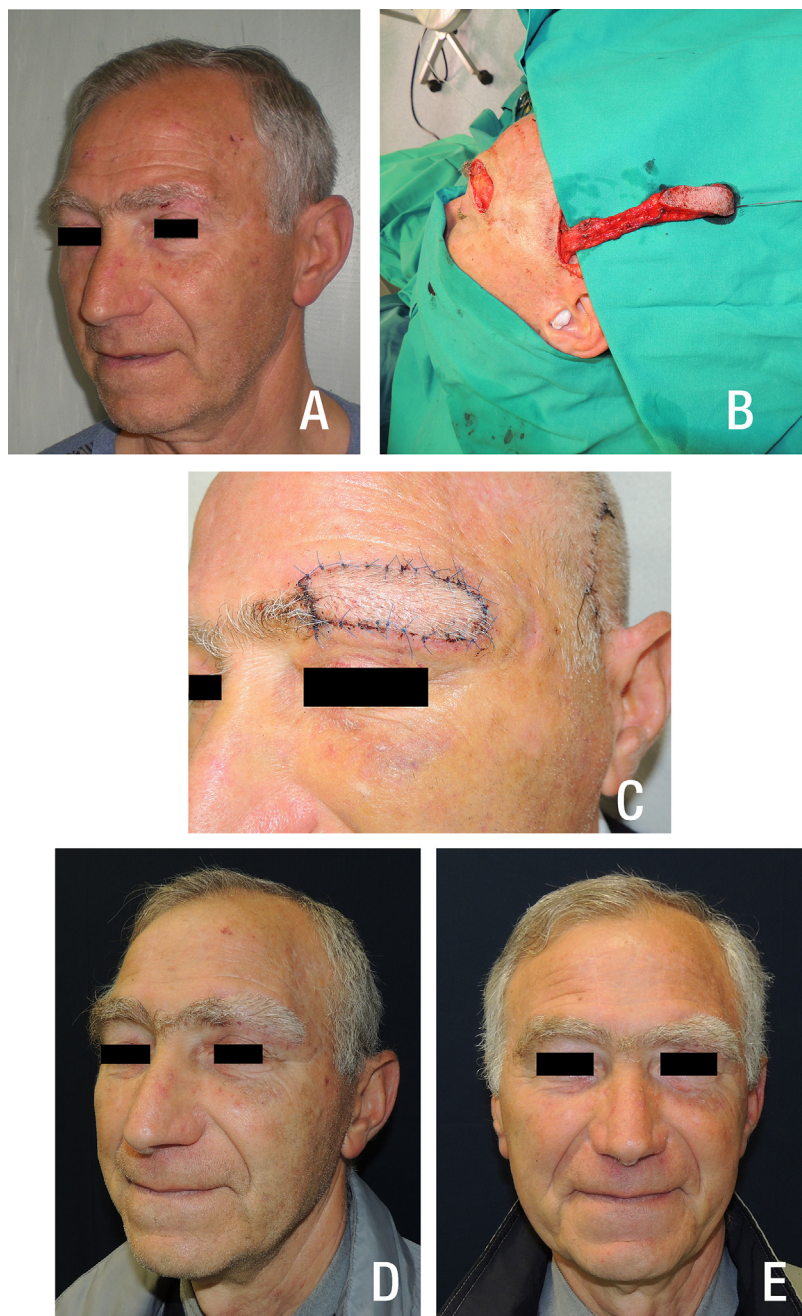


Fig. 5. **A:** Basal cell carcinoma centrally located at the left eyebrow in a 70 years old patient. **B:** 0.3 cm wide local excision of the lesion and superficial temporal artery island flap dissection. **C:** Patient after ten days of follow up. **D:** Superficial temporal artery island flap at 5 months follow up. **E:** 2 years follow up.

Breslow thick melanoma with simultaneous sentinel lymph node biopsy, while the second underwent a 1 cm wide local excision for a 0.6 mm Breslow thick melanoma.

In 21 cases reconstruction was performed with direct closure on patients presenting lesions of less than 1 cm (ranging from 0.5 cm to 0.9 cm). In 4 of the cases defects were treated using a single advancement flap. An H flap was used in 7 patients, whereby the largest defect was 3.5×2.7 cm in dimension. The other 14 cases were treated with V-Y advancement island flaps. Amongst these, 7 patients were treated using a V-Y flap with random vascularization and

subcutaneous pedicle, 4 of which were treated with a single V-Y flap and 3 with a double V-Y advancement flap. Of the others, seven patients were treated with axial vascularization and a more extensive dissection of the vascular pedicle, three of which were treated with a flap dependent on the supra-trochlear artery and four with a flap dependent on the superficial temporal artery. The V-Y reconstruction with random vascularization was performed on defects ranging from 1.5×1.3 to 3×2.8 cm while in axially vascularized V-Y flaps the average size was 3.6×2.6 cm. Two patients with a subtotal eyebrow defect were treated with an STA based island flap for reconstruction.

TABLE I. Visual Analogue Scale Showing Patients' and Observers' Assessment of the Overall Outcome of the Reconstructed Eyebrow at a Mean One Year After Surgery

Patients	Patients satisfaction	Observer 1 evaluation	Observer 2 evaluation	Observer 3 evaluation
1	8	9	9	8
2	10	9	9	9
3	7	6	6	8
4	8	9	9	9
5	10	8	8	10
6	8	8	7	9
7	9	7	7	8
8	8	9	8	8
9	9	10	9	10
10	8	9	8	8
11	9	9	9	9
12	8	8	7	9
13	9	7	7	8
14	7	9	8	7
15	8	9	8	8
16	7	6	6	8
17	7	6	6	8
18	8	8	7	9
19	8	9	9	8
20	8	9	9	8
21	7	9	8	7
22	7	6	6	8
23	7	6	6	8
24	8	9	9	8
25	9	9	10	9
26	7	6	6	8
27	10	8	8	10
28	7	9	8	7
29	9	10	9	10
30	8	8	7	9
31	9	7	7	8
32	8	9	9	8
33	7	6	6	8
34	7	9	8	7
35	7	6	6	8
36	9	10	9	10
37	7	6	6	8
38	8	9	8	8
39	10	8	8	10
40	7	9	8	7
41	8	8	7	9
42	8	9	10	8
43	7	6	6	8
44	10	10	9	10
45	7	9	8	7
46	8	8	7	9
47	8	9	8	8
48	7	6	6	8

All but one flap survived. In one female patient, a heavy smoker, one of the double V-Y advancement flaps experienced distal necrosis which was managed conservatively. Continuity and alignment of eyebrows were achieved satisfactorily. Relative symmetry was also obtained. Hair direction was not preserved and restored in all of the patients. This was predominantly due to the fact that lateral portion of the eyebrow has a different pattern of hair growth from the medial one. Forehead mobility and sensation were preserved including cases with extensive flap mobilization. One female patient experienced a trap door deformity on the upper margin of a single rectangular advancement flap but refused surgical correction. No other significant post-operative complication was observed.

At a mean one year follow up all patients showed no local recurrence nor locoregional lymphadenopathy.

The overall cosmetic outcome was excellent as proved by patient satisfaction and external observer evaluation (Table I). No additional procedure was required.

A reconstructive algorithm for eyebrow flap reconstruction was drawn up following the review of the clinical series and different pedicled flaps were assigned to five possible defect sizes (Fig. 6).

DISCUSSION

A generally acknowledged principle is that in unilateral eyebrow loss, the contralateral eyebrow is used as a model [8] while in bilateral eyebrow loss the new eyebrow site is designed respecting the concept of symmetry [9]. Matsuo et al. [10] identified three main options for eyebrow reconstruction: free hair transfer, free skin graft with hair transfer and flap transfer. Omranifard et al. [11] considers grafting a second option after flaps as hair density is not enough and requires more than two stages to be completed. For partial eyebrow defects the best option is the use of local flaps from the remaining ipsilateral eyebrow which has characteristics that are more similar to those of the recipient site. Rotation flaps, bilobed flaps and transposition flaps are contraindicated because they cannot respect the eyebrow line. Other reconstructive techniques such as tattooing are considered secondary options.

Based upon our experience with the 48 patients who had undergone eyebrow reconstruction surgery at our hospital, a surgical algorithm was elaborated following clinical evaluation of the study's cases, with the intention of guiding surgeons in their choice of the best technique for partial or total eyebrow reconstruction. An algorithm, being a step-by-step guide whereby each step can be followed by only one possible action, eliminates the possibility of misunderstanding and error. In 2011 Ridgway and Pribaz [12] presented a surgical algorithm for the reconstruction of full and partial eyebrow defects by proposing different reconstructive techniques according to the etiology of the defect. Their idea was to reconstruct burn or radiation defects with local flaps while in "no burn" patients, single follicle and hair plug transplants were preferred. In their study vascularized scalp flaps based on the superficial temporal artery were also considered when the recipient bed was not well vascularized.

Our algorithm presented herein focuses on the particular eyebrow defect size and position and is based on our belief that the portion of the eyebrow to be reconstructed is the most important factor in choosing the best reconstructive flap option. Therefore our algorithm is devised to divide eyebrow defects into 5 categories depending on the relative defect size in proportion to the total eyebrow (Fig. 6).

Previously Kim et al. [13] described a technique for single eyebrow reconstruction using two small non-V-Y type flaps, one of which was supplied by the supraorbital artery, where both arteries were completely skeletonized. Silapunt et al. [14] sustained the infeasibility of using a V-Y flap to correct eyebrow defects greater than 1.5 cm due to the impossibility of obtaining the same eyebrow length postoperatively. This aesthetic problem mostly depends on the age of the patient, the elasticity of the skin and on the overall eyebrow length. Moreover, post-operative asymmetry can be bypassed by using a nonsurgical camouflage procedure on the contralateral eyebrow.

In our surgical practice we routinely perform V-Y flaps for defects even greater than 1.5 cm in size although in cases of defects greater than 2.3–2.5 cm, significant technical problems arise when mobilizing the flap for, in our experience, we find that when the defect exceeds 2.5 cm, the "classic" subcutaneous pedicle V-Y flap with random vascularization does not provide sufficient flap mobility and hence it becomes necessary to perform a meticulous dissection of the pedicle [4]. However, dissection exposes the flap to an increased risk of partial or total necrosis. When defects exceed half the length of the eyebrow, the remainder of the aesthetic sub-unit is so exiguous that a good aesthetic result cannot be guaranteed. In these cases, the V-Y flap cannot be used and it becomes necessary to turn to more complex procedures such as the hair bearing scalp transfer. We believe that the "classic" V-Y flap should be used to reconstruct defects not exceeding

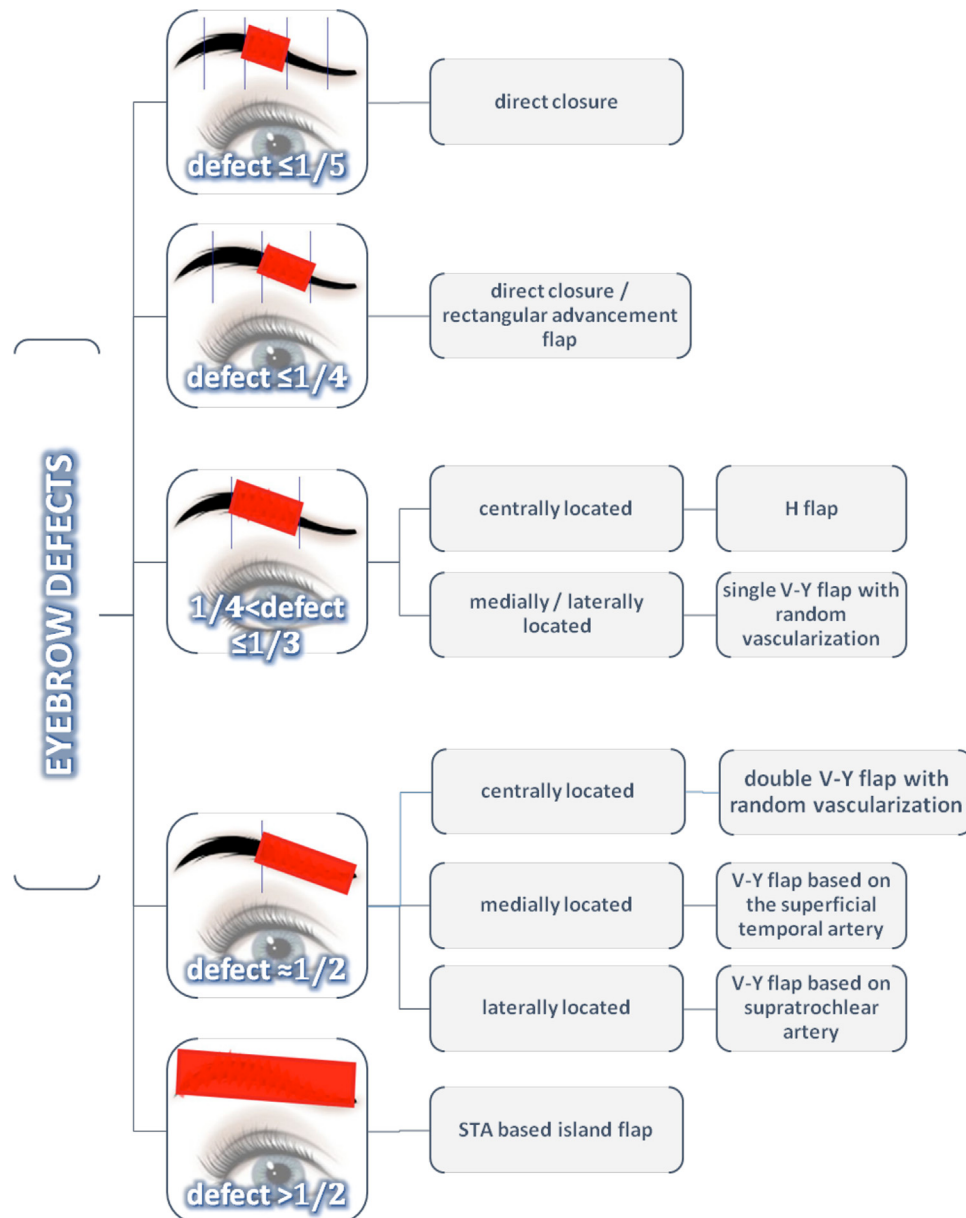


Fig. 6. Eyebrow flap reconstruction algorithm: size of defects and corresponding reconstructive options.

2.5 cm in size, notwithstanding the size of the eyebrow, with consideration given to the fact that eyebrow length varies significantly in the general population.

Barone et al. [15] pointed out that an eyebrow reconstructed by a local flap, despite being symmetric and well-aligned, is by necessity shorter than the contralateral brow due to the fact that no additional hair-bearing tissue is transferred. However the reduction in length of the brow, especially in elderly patients, does not very often result in a noticeable cosmetic defect.

The same authors emphasized the importance of V-Y flaps for eyebrow reconstruction. In particular, the authors described the “free style-like V-Y flap” as an advancement V-Y flap indicated for defects between 30 and 50 % of eyebrow length which gives excellent cosmetic results especially for defects of the medial third of the eyebrow. The V-Y perforator flap they described had a pedicle including perforators

from supratrochlear, supraorbital or superficial temporalis artery depending on the site to repair.

Tenna et al. [16] described the use of vascularised pedicled temporoparietal fascia in a wide range of clinical situations extending from auricular reconstruction and facial soft tissue augmentation to skull base, orbital and intraoral reconstruction. In particular, the authors considered the superficial temporal artery island flap a valuable option for the reconstruction of more than half of the length of the eyebrow thanks to its antegrade flow for hair-bearing, soft-tissue transfer. Ridgway et al. [12] emphasized the importance of performing this procedure, especially for male defects, due to the thicker nature of male eyebrows. As suggested by Juri[17] and based on our experience, we favour an island flap harvested from the lateral parietal area which is usually not affected by alopecia. In addition, we have found that when the island flap is placed on the recipient site, hair will grow in its natural

direction, while island flaps from the frontal area cannot guarantee this cosmetic result.

CONCLUSIONS

Reconstruction of eyebrow defects is not a simple procedure and presents a formidable challenge to the plastic surgeon. Several surgical techniques can be used to repair partial and total eyebrow defects, each with its specific application, advantage and limits.

Great enthusiasm has been given to the standardization of the V-Y flap technique for the reconstruction of the eyebrow subunit. Our experience tells us that the key to achieving good aesthetic results is to choose the appropriate flap design. The algorithm presented herein, together with the proposed techniques, can provide the plastic surgeon with a direct, fool-proof approach for reconstructing any given eyebrow defect.

ACKNOWLEDGMENT

Juliet Ippolito, B.A. Vassar College, M Phil University of Dundee for English language editing.

REFERENCES

1. Fattahi T: An overview of facial aesthetic units. *J Oral Maxillofac Surg* 2003;61:1207–1211.
2. Dessy LA, Figus A, Fioramonti P, et al.: Reconstruction of anterior auricular conchal defect after malignancy excision: Revolving-door flap versus full-thickness skin graft. *J Plast Reconstr Aesthet Surg* 2010;63:746–752.
3. Kleintjes WG: Forehead anatomy: Arterial variations and venous link of the midline forehead flap. *J Plast Reconstr Aesthet Surg* 2007;60:593–606.
4. Schonauer F, Taglialatela Scafati S, Molea G: Supratrochlear artery based V-Y flap for partial eyebrow reconstruction. *J Plast Reconstr Aesthet Surg* 2010;63:1391–1392.
5. Stamatopoulos C, Alexakis R, Tsoutsos D, et al.: The use of temporal artery flaps in defects the head and neck. *Ann Medil Burns Club* 1994;VII.
6. Motamed S, Davami B: Eyebrow reconstruction following burn injury. *Burns* 2005;31:495–499.
7. Omranifard M, Doosti MI: A trial on subcutaneous pedicle island flap for eyebrow reconstruction. *Burns* 2010;36:692–697.
8. Gunter JP, Antrobus SD: Aesthetic analysis of the eyebrows. *Plast Reconstr Surg* 1997;99:1808–1816.
9. Guyron B, Cohen SR: Facial evaluation for orthogenetic surgery. In: Ferraro JW, editor. *Maxillofacial surgery*. New York: Springer; 1997. pp. 224–232. chapter 12.
10. Matsuo S, Hashimoto I, Seike T, et al.: Extended Hair-bearing Lateral Orbital Flap for Simultaneous Reconstruction of Eyebrow and Eyelid. *Plast Reconstr Surg* 2014;2:e111.
11. Omranifard M, Koushki AM: Comparison of four surgical methods for eyebrow reconstruction. *Indian J Plast Surg* 2007;40:147–152.
12. Ridgway EB, Pribaz JJ: The reconstruction of male hair-bearing facial regions. *Plast Reconstr Surg* 2011;127:131–141.
13. Kim KS, Hwang JH, Kim DY, et al.: Eyebrow island flap for reconstruction of a partial eyebrow defect. *Ann Plast Surg* 2002;48:315–317.
14. Silapunt S, Goldberg LH, Peterson RS, et al.: Eyebrow reconstruction: Option for reconstruction of cutaneous defects of the eyebrow. *Dermatol Surg* 2004;30:530–535.
15. Leto Barone AA, Rossi M, Giunta G, et al.: A Freestyle-like V-Y flaps of the eyebrow: A new outlook and indication of an historical technique. *Sci World J* 2013;182518.
16. Tenna S, Brunetti B, Aveta A, et al.: Scalp reconstruction with superficial temporal artery island flap: Clinical experience on 30 consecutive cases. *J Plast Reconstr Aesthet Surg* 2013;66:660–666.
17. Juri J: Eyebrow reconstruction. *Plast Reconstr Surg* 2001;107:1225–1228.