

F. Schonauer · G. Fera · I. LaRusca · G. Molea

Splintage for correction of congenital ear deformities

Received: 11 June 2003 / Accepted: 19 June 2003 / Published online: 23 September 2003
© Springer-Verlag 2003

Abstract Many congenital ear deformities involve abnormal plical folding, most commonly affecting the helix and the antihelix. Non-hypoplastic auricular deformities can be corrected by appropriate splinting in the early neonatal period without anaesthetic and with minimal cost. At this time, oestrogen activity is increased and the ear cartilage is very malleable. The splinting therapy, devised and popularized in Japan, has not been widely used in Europe. A series of 26 patients having various ear deformities treated by splintage in the early neonate period is presented. Excellent results were achieved in 82% of the splinted ears. In the other 18% results were satisfactory or good. No complications occurred in the series. In conclusion, ear splintage is an effective technique that should be more frequently offered to parents of affected neonates.

Keywords Congenital · Ear · Splintage · Non-surgical

Introduction

In 1982 Kurozomi, et al. [1] described a case in which an unusual congenital ear deformity was treated successfully by splinting with Reston foam. Matsuo et al., 2 years later [2] used non-surgical correction of various ear deformities in 150 patients below 1 year of age. They suggested that almost all cases could be non-surgically corrected in early neonates. They subsequently published their results in a larger series of patients and concluded that non-surgical treatment was better than surgical correction and should be tried at least once in the early neonatal period [3].

Presented at the 14th Annual Meeting of the European Association of Plastic Surgeons (EURAPS), Vienna, Austria, 29–31 May, 2003

F. Schonauer (✉) · G. Fera · I. LaRusca · G. Molea
Department of Plastic Surgery,
University of Naples “Federico II”, Naples, Italy
e-mail: fschona@libero.it
Tel.: +39-335-436692, Fax: +39-081-2482114

In 1994, Tan, et al. [4] used the splintage technique to treat seven boys and three girls with various types of ear deformities (14 ears) between 6 h and 5 months after birth with a follow-up period of 6–35 months. The results were satisfactory in all but one child.

It is very hard to classify the various types of congenital ear deformities. Terms such as “lop ear”, “shell ear”, “lidded helix”, “cup ear” and “canoe ear” have been applied to various form of ear anomalies.

In our experience four groups of ear deformities can be treated by splintage: constricted ear, Stahl’s ear, helical contour deformity and bat ear.

In 1975 Tanzer [5] proposed a classification of a group of ear anomalies in which the rim of the ear looks as though it has been tightened, rather like a purse string that has been pulled closed. He called these deformities constricted ear and divided them into three groups: (1) involvement of the helix alone; (2) involvement of the helix and scapha; and (3) extreme cupping deformity:

- Stahl’s ear is an auricular deformity characterized by the presence of a third crus; this is usually formed by an abnormal cartilaginous fold extending from the antihelix, across the scapha, to the helical rim. The area of the helix affected by the third crus may present a flat appearance. The degree of this deformity differs from case to case.
- Helical contour deformities are very frequent; they include kinking, folding inside of the helix or other deformities that modify the helical rim.
- Bat ear is a very frequent deformity. The most common causes of protrusion of the external ear are an underdeveloped or absent antihelical fold, an excessively deep concha or a combination of both these features.

Materials and Methods

Our technique is based on the use of a wire core segment in a 6-Fr Silastic tube (Fig. 1). The splint is shaped and positioned in the

groove between the helix and the antihelix. It is held in place with three to five Steri-Strips (Fig. 2). Splintage is applied with no anesthesia. In constricted ears and in cases of helical contour deformities, interest is given primarily to recreate the normal relationship between the helix and the antihelix. In Stahl's ear the aim of the splintage is to "press out" the abnormal fold in the scapha, and to mould the scapha in the normal concavity; sometimes it is necessary to recreate the helical rim. Bat ear is corrected by affixing the helical rim to the posterior retro-auricular region with surgical tapes, thereby forcing the auricular-cephalic angle towards the mastoid. An elastic bandage or a headband is used for reinforcement. Satisfactory correction is usually obtained after 2 weeks; the splintage is then continued thereafter until the result is stabilized, which takes at least one more week (Fig. 3, Fig. 4, Fig. 5).

Results

In the last 18 months we treated 26 infants with 36 deformed ears (10 bilateral and 16 unilateral deformities): nine constricted ears, seven Stahl's ears, ten helical contour deformities and ten bat ears. The period of splint application ranged between 2 and 6 weeks. Informed parental consent was obtained in all cases. Almost all the treated ears improved significantly within the first 1 or 2 weeks after the application of the splintage. Bat ear was the most difficult deformity to treat and required a longer period of splintage than the other deformities. Our follow-up ranged between 2 and 6 months. The results were excellent in 82% of cases, satisfactory in 11% and



Fig. 1 Splint materials

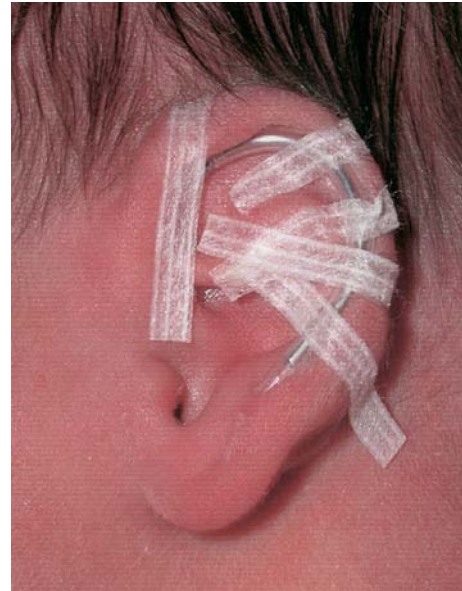

Fig. 2 Splint application

Fig. 3 **A** Stahl's ear at day 3.
B Follow-up at 6 months

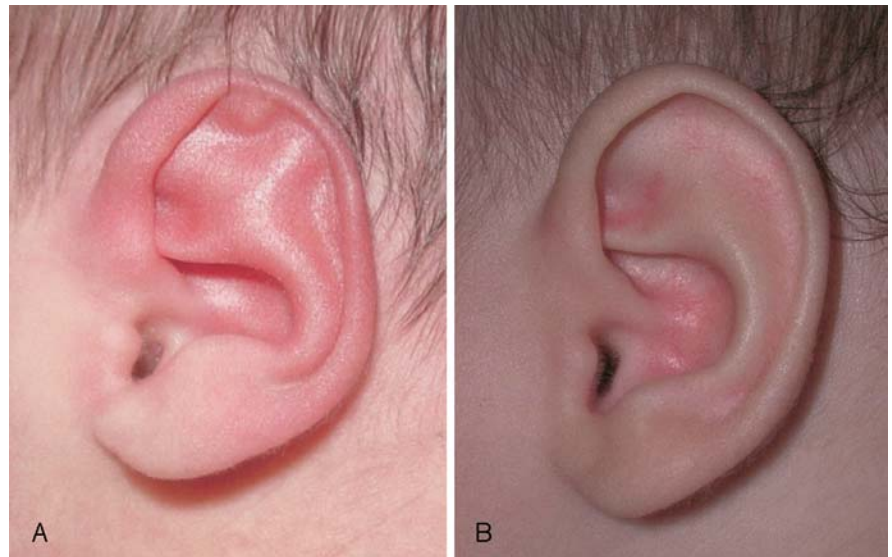


Fig. 4 **A** Constricted ear at day 3.
B Follow-up at 4 weeks

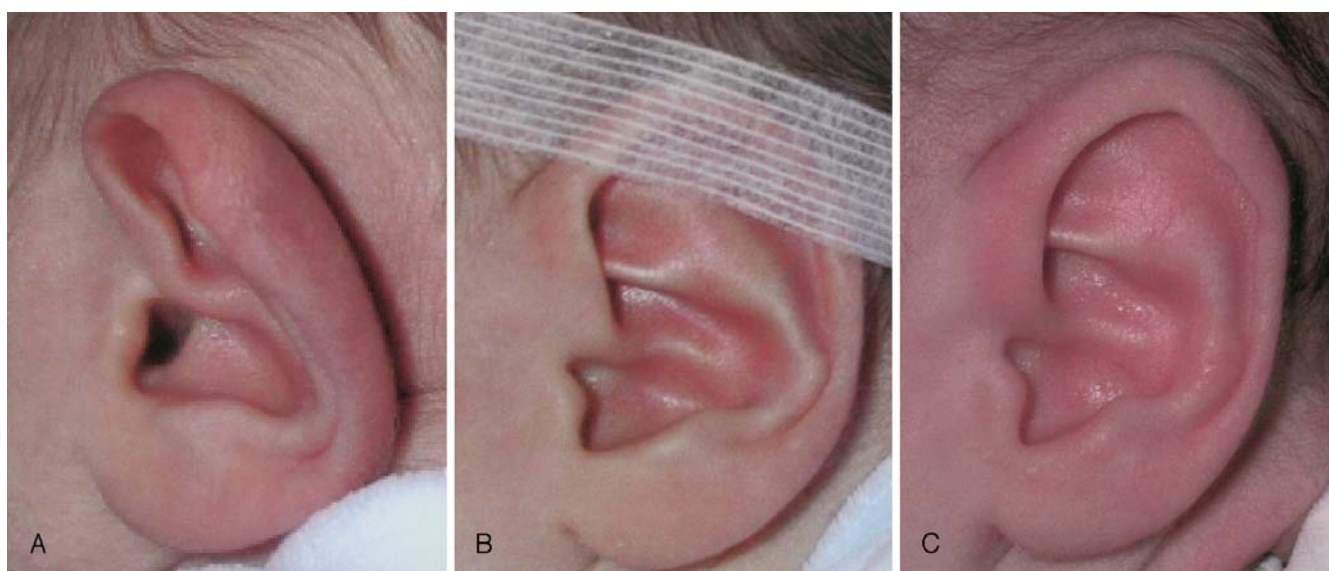
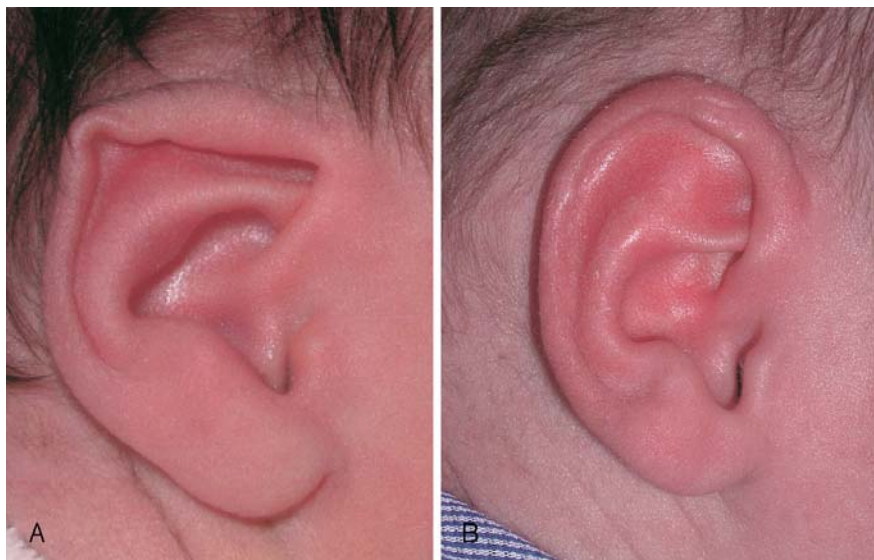

Fig. 5 **A** Unilateral bat ear. **B** Bat ear splintage at day 3. **C** Follow-up at 3 months

Table 1 Clinical results

Ear deformity	<i>n</i>	Improved	Satisfactory	Excellent	Abandoned/lost to follow-up
Constricted ear	9			8	1
Stahl's ear	7			5	2
Helical contour deformity	10		2	6	2
Bat ear	10	2	1	4	3
Total	36	2	3	23	8
Follow-up	28	7%	11%	82%	–

improved in 7%. Eight newborns did not complete the treatment or were lost to follow-up (Table 1). No complications such as skin necrosis or allergy to Steri-Strips were detected.

Discussion

The neonatal ear is soft and malleable. Within a few days after birth the ear becomes more elastic and firmer. This is related to the blood oestrogen levels. In fact, circulating levels of free oestradiol are highest during the first

72 h after birth and decrease rapidly thereafter. Thus, “congenital” ear deformities can be treated more effectively in the early neonatal period. Non-surgical correction of auricular deformities has been carried out in children older than early neonates, although the results were good in only 50% of cases [6].

There is no agreement as to what contour irregularities constitute “deformities” that should be corrected. When we see a neonate with a congenital ear deformity that could respond to splinting, we wait at least 48 h because the deformity can disappear spontaneously. Therefore, we usually apply the splint 3 days after birth. Neonates returned to the clinic for weekly follow-ups until the deformity was corrected and the ear position stable, which usually took from 3 to 4 weeks. We believe that splinting is not a procedure that can be carried out by parents. In fact often the splint must be adjusted depending on the evolution in the deformity correction.

We conclude that ear splintage is an effective procedure that should be more frequently offered to parents of affected neonates. The technique is simple, cheap and reproducible. We recommend a wider use of the method among neonatologists, paediatricians and nursing staff.

References

1. Kurozumi N, Ono S, Ishida H (1982) Non surgical correction of a congenital lop ear deformity by splinting with Reston foam. *Br J Plast Surg* 35:181
2. Matsuo K, Hirose T, Tomono T, Iwasawa M, Katohda S, Takahashi N, Koh B (1984) Nonsurgical correction of congenital auricular deformities in the early neonate: a preliminary report. *Plast Reconstr Surg* 73:38
3. Matsuo K, Hajashi R, Kijono M, Hirose T, Netsu Y (1990) Nonsurgical correction of congenital auricular deformities. *Clin Plast Surg* 17:383
4. Tan ST, Shibu M, Gault DT (1994) A splint for correction of congenital ear deformities. *Brit J Plast Surg* 47:575
5. Tanzer RC (1975) The constricted (cup and lop) ear. *Plast Reconstr Surg* 55:406
6. Yotsuyanagi T, Yokoi K, Urushidate S, Sawada Y (1998) Non-surgical correction of congenital auricular deformities in children older than early neonates. *Plast Reconstr Surg* 101:907